

## Fungal keratitis in Songklanagarind Hospital

จักรี หิรัญแพทย์<sup>1</sup>

นิยะดา มะแซ<sup>2</sup>

### Abstract:

#### Fungal keratitis in Songklanagarind Hospital

Hirunpat C, Masae N.

Department of Ophthalmology, Faculty of Medicine,

Prince of Songkla University, Hat Yai, Songkhla, 90110, Thailand

Songkla Med J 2005;23(6):429-434

**Objective:** To evaluate spectrum of disease and risk factors associated with corneal complication.

**Design:** Retrospective study

**Materials and methods:** A total of 76 medical records of fungal culture-positive keratitis treated at Songklanagarind Hospital from 1982 to 2003 were reviewed. Factors associated with corneal complication were analyzed.

**Results:** Mean age of this group was  $46.4 \pm 16.3$  years. Fifty five patients (71%) were males. Before the initial symptoms, 50 patients (66%) had a history of eye trauma from several materials, such as leaves, branches, dust and sand. The median delay between the initial symptoms and fungal keratitis treatment was 13.5 days (range 3-87 days). The most common fungi found were *Fusarium* species (71%). The initial topical antifungal drugs most frequently used were amphotericin B, ketoconazole and natamycin. Corneal complications included corneal perforation and near total corneal infiltration requiring further surgery such as penetrating keratoplasty, evisceration and enucleation. Being female, poor initial best-corrected visual acuity (BCVA) and having a longer treatment delay had a higher risk of corneal complication.

---

<sup>1</sup>MD., Dip. Thai Board of Ophthalmology <sup>2</sup>RN., B.Sc., Department of Ophthalmology, Faculty of Medicine, Prince of Songkla University, Hat Yai, Songkhla, 90110, Thailand

รับต้นฉบับวันที่ 3 มีนาคม 2548 รับลงตีพิมพ์วันที่ 11 มกราคม 2549

**Conclusions:** *Fusarium* species is the most common cause of fungal keratitis in southern Thailand. Ophthalmologists should be concerned about corneal complications among patients who are female, have poor initial BCVA and delay of treatment.

**Key words:** fungal keratitis, *Fusarium* species, corneal complication, corneal perforation, near total corneal infiltration, evisceration, enucleation, penetrating keratoplasty, female, best-corrected visual acuity

## บทคัดย่อ:

**วัตถุประสงค์:** เพื่อประเมินลักษณะของโรคติดเชื้อราที่กระจกตาและปัจจัยเสี่ยงที่สัมพันธ์กับภาวะแทรกซ้อนที่กระจกตา

**รูปแบบวิจัย:** การศึกษาย้อนหลัง

**วัสดุและวิธีการ:** ศึกษาข้อมูลเวชระเบียนผู้ป่วยในของโรงพยาบาลสงขลานครินทร์ตั้งแต่ปี พ.ศ. 2525 ถึง พ.ศ. 2546 วิเคราะห์ปัจจัยที่สัมพันธ์กับภาวะแทรกซ้อนที่กระจกตา

**ผลการศึกษา:** อายุเฉลี่ยของผู้ป่วยเท่ากับ  $46.4 \pm 16.3$  ปี เป็นเพศชาย 55 ราย (ร้อยละ 72) ผู้ป่วย 50 ราย (ร้อยละ 66) มีประวัติสิ่งแปลกปลอมเข้าตา เช่น ใบไม้ กิ่งไม้ ฝุ่น และทราย ค่าเฉลี่ยของเวลาตั้งแต่ผู้ป่วยเริ่มมีอาการจนกระทั่งได้รับการรักษาเท่ากับ 13.5 วัน (3-87 วัน) เชื้อราที่พบบ่อยที่สุด คือ *Fusarium* species (ร้อยละ 71) ยาหยอดตาที่เริ่มใช้บ่อยที่สุด ได้แก่ amphotericin B, ketoconazole และ natamycin ภาวะแทรกซ้อนที่กระจกตา ได้แก่ กระจกตาทะลุและมีการติดเชื้อเกือบทั่วกระจกตา ซึ่งต้องการการผ่าตัดรักษาเพิ่มเติม ได้แก่ เปลี่ยนกระจกตา ควักลูกตา ปัจจัยเสี่ยงของการเกิดภาวะแทรกซ้อนของกระจกตา ได้แก่ เพศหญิง การมองเห็นที่ดีที่สุดก่อนเริ่มการรักษาที่ไม่ดี และได้รับการรักษาล่าช้า

**สรุป:** *Fusarium* species เป็นสาเหตุของการติดเชื้อที่กระจกตาที่พบบ่อยที่สุดในภาคใต้ของประเทศไทย จักษุแพทย์ควรตระหนักถึงภาวะที่แทรกซ้อนที่กระจกตาในกลุ่มผู้ป่วยที่เป็นเพศหญิง การมองเห็นที่ดีที่สุดก่อนเริ่มการรักษาที่ไม่ดี และได้รับการรักษาล่าช้า

**คำสำคัญ:** การติดเชื้อที่กระจกตาจากเชื้อรา, *Fusarium* species, ภาวะแทรกซ้อนที่กระจกตา, กระจกตาทะลุ, การติดเชื้อเกือบทั่วกระจกตา, การควักตา, การเปลี่ยนกระจกตา, เพศหญิง, การมองเห็นที่ดีที่สุด

## Introduction

Fungal keratitis continues to be an important cause of ocular morbidity, particularly in the agricultural communities of the developing world. It is frequently caused by species of *Fusarium*,<sup>1-6</sup> *Aspergillus*,<sup>1-2,4-6</sup> *Curvularia*,<sup>1-2,5</sup> and *Candida*.<sup>1,3-4</sup> It tended to occur in healthy male patients<sup>2</sup> who had been subjected to outdoor trauma and contaminated with soil or plant. The most important predisposing cause is ocular trauma.<sup>1-2,4</sup> Contact lens wear, chronic ocular surface disease, prior application of broad spectrum antibiotics and corticosteroids are also important risk factors.<sup>3-4,7-8</sup> Reported cases after excimer laser treatment have been increasing in recent years.<sup>9-19</sup> Fungi are also present in the conjunctival sacs<sup>20</sup> of asymptomatic individuals which may be a source of infection in some traumatic eyes. It is a sight-threatening infection of the cornea

that sometimes leads to loss of the eye. Too large lesions before starting treatment may be from treatment delay, high virulence of infection or underlying host diseases. The limited corneal penetration efficacy of antifungal medication leads to poor response of deep corneal infiltration even with good drug sensitivity in vitro.

## Materials and methods

All medical records of infectious keratitis admitted to Songklanagarind Hospital from 1982 to 2003 were identified based on the ICD 10 code H16.0. All culture-positive fungal keratitis cases were selected. Patients who had unknown final clinical course such as referring for keratoplasty, or denied having further treatment were excluded from this study. We

defined corneal complications as a corneal perforation or a near total corneal infiltration that required any surgical interventions. The initial BCVA is divided into two groups: good initial BCVA, defined as vision better than 5/200 and poor initial BCVA, defined as vision equal to or worse than 5/200. The STATA program was used for data analysis.

The Medical Sciences Subcommittee for the Protection of Human Subjects at the Songklanagarind Hospital approved a retrospective review of all medical records.

## Results

### Epidemiology

A diagnostic and therapeutic corneal scraping/debulking was performed on each patient at presentation. Eighty five patients (15%) of culture-positive fungal keratitis were identified from 556 patients of infectious keratitis. Nine patients were excluded because of unknown final clinical course. Of the remaining 76 patients, 55 cases (72%) were males. The mean age at presentation was  $46.4 \pm 16.3$  years. The age distribution is shown in Figure 1. *Fusarium* species was the most common fungus involvement in this disease. There was one case of triple fungal infection: *Fusarium*, *Aspergillus*, and *Curvularia* species (Table 1).

Before the initial symptoms, 50 patients (66%) had a history of eye trauma from several materials, including leaf, branch, insect, dust and sand. The delay between the first symptoms and fungal keratitis treatment was 13.5 days (range 3-87 days).

### Medical treatment

Twenty seven cases (36%) received amphotericin B alone. Six patients (8%) received natamycin alone. Seven cases (9%) received topical ketoconazole alone. Two cases were diagnosed as fungal keratitis after evisceration shortly after admission and had never received any antifungal drugs. Nearly half of all patients received some forms of antifungal drug combination.

### Complications and surgical interventions

There were 20 cases (26%) of corneal complication, which required some form of surgery such as gluing, scleral

graft and penetrating keratoplasty. In this group, evisceration or enucleation was performed in 15 cases of corneal perforation or near total corneal infiltration which did not respond to medical treatment. Table 2 shows that sex and initial BCVA were significantly associated with corneal complication. *Fusarium* species was not statistically significantly associated with corneal complication. From the multivariate analysis we found that sex, initial BCVA and treatment delay were associated with corneal complication. Being female, poor initial BCVA and having longer treatment delay had a higher risk of corneal complication as shown in Table 3.

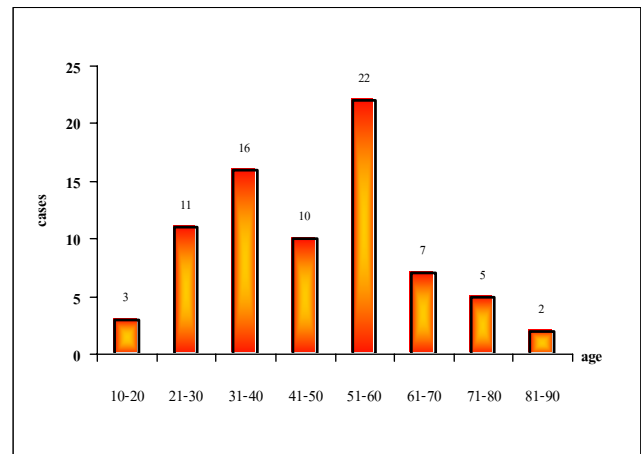


Figure 1 Age distribution of fungal keratitis patients

Table 1 Distribution of occurrence of fungal keratitis

Fungal species	Cases (N = 76)
<i>Fusarium</i>	49 (64.5%)
<i>Aspergillus</i>	8 (10.5%)
<i>Curvularia</i>	5 (6.6%)
<i>Candida</i>	2 (2.6%)
<i>Cepharosporium</i>	2 (2.6%)
<i>Acremonium</i>	1 (1.3%)
<i>Pythium</i>	1 (1.3%)
<i>Fusarium + Aspergillus + Curvularia</i>	1 (1.3%)
Unidentified	7 (9.2%)

Table 2 Risk factors of corneal complication

Variable	Number (%)		P-value
	No corneal complication (N=56)	Corneal complication (N=20)	
Age group (year)			0.296
≤ 30	11 (78.6)	3 (21.4)	
31-60	37 (77.1)	11 (22.9)	
> 60	8 (57.1)	6 (42.9)	
Sex			0.009
male	45 (81.8)	10 (18.2)	
female	11 (52.4)	10 (47.6)	
Initial BCVA <sup>β</sup>			< 0.001
Good	33 (97.1)	1 (2.9)	
Poor	22 (55.7)	19 (46.3)	
Patient and doctor delay (days)	12.5 (3-61)	18.5 (5-87)	0.064 <sup>π</sup>

β Good >5/200, poor ≤ 5/200

π = Mann-Whitney test

Table 3 Association between risk factors and corneal complication

Variable	Crude OR (95% CI)	P-value	Adjusted OR (95% CI)	P-value
<b>Initial BCVA</b>				
Good	1	0.002	1	0.002
Poor	28.5 (3.6-228.6)		33.6 (3.5-326.0)	
<b>Sex</b>				
Male	1	0.012	1	0.027
Female	4.1 (1.4-12.3)		4.7 (1.2-18.8)	
<b>Patient and doctor delay</b>	1.03 (1.00-1.07)	0.053	1.05 (1.01-1.09)	0.035

## Discussion

*Fusarium* species was the most common fungi in our study. Being female, having poor initial BCVA and delay of treatment were significantly associated with corneal complication.

In our study, corneal complication was not statistically significantly associated with *Fusarium* species. This is contrast to Vemuganti,<sup>6</sup> who studied about the histology and microbiology, and found that the risk factors for corneal perforation were fungal load, depth of infiltration, and *Fusarium* species.

We found that females had a significant association with corneal complication. However, this association contrasts with other studies.<sup>6, 21</sup> The explanation of this result remains questionable.

Having poor initial clinical manifestation could be finalized with poor outcome. Tanure found that poor initial BCVA was associated with poor final BCVA.<sup>3</sup> We also found it was associated with corneal complication.

The result of this study revealed that patients with delayed treatment were more likely to have corneal compli-

cations. This finding is similar to that of a study from Gopinathan.<sup>2</sup>

It might be noted that during the period of this study, our hospital was faced with certain limitations in treatment, for instance the unavailability of natamycin together with a lack of corneal donors in the early period. N-butyl cyanoacrylate,<sup>21</sup> human fibrin glue,<sup>22</sup> conjunctival flap<sup>23</sup> and amniotic membrane transplantation<sup>22, 24</sup> are useful modalities for the management of corneal perforation associated with infective keratitis. Penetrating keratoplasty (PKP) is an effective treatment in fungal keratitis.<sup>2-3, 6, 21, 25-26</sup> Its advantages are to get rid of infection and to clear opacity. Early surgical intervention before advanced stage of disease could be done. However, we did not perform PKP in this group due to the advanced stage of disease at the beginning period and the lack of corneal donors at that time. Evisceration and enucleation are operations we had to perform to eliminate the infection.

## Conclusion

***Fusarium* species are the most common organism found in fungal keratitis in southern Thailand. Being female, having poor initial BCVA and delayed treatment are risk factors for corneal complications. This correlation could be of concern in any patient presenting with a fungal keratitis.**

## Acknowledgements

This research was funded by Faculty of Medicine, Prince of Songkhla University. I would like to thank Miss Apiradee Lim for her help on data analysis.

## References

1. Thomas PA. Fungal infections of the cornea. *Eye* 2003; 17:852-62.
2. Gopinathan U, Garg P, Fernandes M, Sharma S, Athmanathan S, Rao GN. The epidemiological features and laboratory results of fungal keratitis: a 10-year review at a referral eye care center in south India. *Cornea* 2002;21:555-9.
3. Tanure MA, Cohen EJ, Sudesh S, Rapuano CJ, Laibson PR. Spectrum of fungal keratitis at Wills Eye Hospital, Philadelphia, Pennsylvania. *Cornea* 2000;19:307-12.
4. Rosa RH, Miller D, Alfonso EC. The changing spectrum of fungal keratitis in south Florida. *Ophthalmology* 1994;101:1005-13.
5. Boonpasart S, Kasetsuwan N, Puangsricharern V, Pariyakanok L, Jitpoonkusol T. Infectious keratitis at King Chulalongkorn Memorial Hospital: a 12-year retrospective study of 391 cases. *J Med Assoc Thai* 2002; 85 Suppl 1:S217-30.
6. Vemuganti GK, Garg P, Gopinathan U, Naduvilath TJ, John RK, Buddi R, et al. Evaluation of agent and host factors in progression of mycotic keratitis: a histologic and microbiologic study of 167 corneal buttons. *Ophthalmology* 2002;109:1538-46.
7. Djalilian AR, Smith JA, Walsh TJ, Malech HL, Robinson MR. Keratitis caused by *Candida glabrata* in a patient with chronic granulomatous disease. *Am J Ophthalmol* 2001;132:782-3.
8. O'Day DM, Ray WA, Head WS, Robinson RD, Williams TE. Influence of corticosteroid on experimentally induced keratomycosis. *Arch Ophthalmol* 1991; 109:1601-4.
9. Periman LM, Harrison DA, Kim J. Fungal keratitis after photorefractive keratectomy: delayed diagnosis and treatment in a co-managed setting. *J Refract Surg* 2003; 19:364-6.
10. Pache M, Schipper I, Flammer J, Meyer P. Unilateral fungal and mycobacterial keratitis after simultaneous laser in situ keratomileusis. *Cornea* 2003;22:72-5.
11. Karp CL, Tuli SS, Yoo SH, Vroman DT, Alfonso EC, Huang AH, et al. Infectious keratitis after LASIK. *Ophthalmology* 2003;110:503-10.
12. Verma S, Tuft SJ. *Fusarium solani* keratitis following LASIK for myopia. *Br J Ophthalmol* 2002;86:1190-1.
13. Ritterband D, Kelly J, McNamara T, Kresloff M, Koplin R, Seedor J. Delayed-onset multifocal polymicrobial

- keratitis after laser in situ keratomileusis. *J Cataract Refract Surg* 2002;28:898-9.
14. Peng Q, Holzer MP, Kaufer PH, Apple DJ, Solomon KD. Interface fungal infection after laser in situ keratomileusis presenting as diffuse lamellar keratitis. A clinicopathological report. *J Cataract Refract Surg* 2002;28:1400.
  15. Kuo IC, Margolis TP, Cevallos V, Hwang DG. *Aspergillus fumigatus* keratitis after laser in situ keratomileusis. *Cornea* 2001;20:342-4.
  16. Kouyoumdjian GA, Forstot SL, Durairaj VD, Damiano RE. Infectious keratitis after laser refractive surgery. *Ophthalmology* 2001;108:1266-8.
  17. Sridhar MS, Garg P, Bansal AK, Gopinathan U. *Aspergillus flavus* keratitis after laser in situ keratomileusis. *Am J Ophthalmol* 2000;129:802-4.
  18. Read RW, Chuck RS, Rao NA, Smith RE. Traumatic *Acremonium atrogriseum* keratitis following laser-assisted in situ keratomileusis. *Arch Ophthalmol* 2000;118:418-21.
  19. Chung MS, Goldstein MH, Driebe WT, Schwartz B. Fungal keratitis after laser in situ keratomileusis: a case report. *Cornea* 2000;19:236-7.
  20. Ando N, Takatori K. Fungal flora of the conjunctival sac. *Am J Ophthalmol* 1982;94:67-74.
  21. Garg P, Gopinathan U, Nutheti R, Rao GN. Clinical experience with N-butyl cyanoacrylate tissue adhesive in fungal keratitis. *Cornea* 2003;22:405-8.
  22. Duchesne B, Tahi H, Galand A. Use of human fibrin glue and amniotic membrane transplant in corneal perforation. *Cornea* 2001;20:230-2.
  23. Khodadoust A, Quinter AP. Microsurgical approach to the conjunctival flap. *Arch Ophthalmol* 2003;121:1189-93.
  24. Rodriguez-Ares MT, Tourino R, Lopez-Valladares MJ, Gude F. Multilayer amniotic membrane transplantation in the treatment of corneal perforations. *Cornea* 2004;23:577-83.
  25. Xie L, Dong X, Shi W. Treatment of fungal keratitis by penetrating keratoplasty. *Br J Ophthalmol* 2001;85:1070-4.
  26. Killingsworth DW, Stern GA, Driebe WT, Knapp A, Dragon DM. Results of therapeutic penetrating keratoplasty. *Ophthalmology* 1993;100:534-41.