

Case Report

รายงานผู้ป่วย: รูเปิดหน้าใบหูอักเสบจากเชื้อวัณโรค

Case Report: Tuberculosis of Preauricular Abscess

กชพร วงษ์สุวรรณ, พ.บ.

Kotchporn Wongsuwan, M.D.

สาขาวิชาโสต ศอ นาสิกวิทยา ศูนย์การแพทย์ปัญญานันทภิกขุ ชลประทาน มหาวิทยาลัยศรีนครินทรวิโรฒ อ.ปากเกร็ด
จ.นนทบุรี 11120 ประเทศไทย

Division of Otolaryngology, Panyanantaphikkhu Chonprathan Medical Center, Srinakharinwirot University,
Pakkred, Nonthaburi 11120, Thailand.

E-mail: kotchporn@g.swu.ac.th

Songkla Med J 2017;35(3):273-276

บทคัดย่อ:

เชื้อวัณโรคก่อให้เกิดโรคได้แก่ทุกส่วนของร่างกาย การติดเชื้อของรูเปิดหน้าหูส่วนใหญ่เกิดจากเชื้อแบคทีเรีย รายงานผู้ป่วยนี้เป็นกรณีของฝีหน้าหูที่เกิดจากเชื้อวัณโรค วัณโรคของฝีหน้าหูไม่เคยมีการรายงานมาก่อนและเกิดจากสาเหตุเดียวกันของวัณโรคผิวหนัง การรักษาทำได้ด้วยยาต้านวัณโรคสูตรมาตรฐานและการผ่าตัด รายงานผู้ป่วยรายนี้ทำให้นักถึงการติดเชื้อวัณโรคในฝีหน้าหูในกรณีที่การรักษาไม่ตอบสนองต่อยาปฏิชีวนะและการผ่าระบายหนอง

คำสำคัญ: รูเปิดหน้าใบหูแต่กำเนิด, วัณโรคนอกปอด, วัณโรคผิวหนัง

Abstract:

Tuberculosis (TB) can infect any part of the body. Preauricular sinus is a congenital anomaly of the external ear. Infection of the preauricular sinus is mainly caused by bacteria. This is a case report of TB of preauricular abscess which presented with an unresponsive abscess to an antibiotic. TB of preauricular abscess is extremely rare, and assumed to have the same etiology as cutaneous tuberculosis. Treatments are standard anti-TB drugs with excision of preauricular sinus. This case emphasizes the consideration of TB in a preauricular abscess that does not respond to antibiotics, incision and drainage.

Keywords: cutaneous tuberculosis, extrapulmonary tuberculosis, preauricular abscess, tuberculosis

รับต้นฉบับวันที่ 8 กุมภาพันธ์ 2560 รับลงตีพิมพ์วันที่ 28 มีนาคม 2560

Introduction

Tuberculosis (TB) can affect any part of the body and the manifestations can be an imitation. About 18.0–47.0% of TB in Thailand is extrapulmonary TB.^{1,2} Young age, female, Asian and African origin, and human immunodeficiency virus infection are independent risk factors for extrapulmonary TB.³ Lymphadenitis is the most common form of extrapulmonary TB¹ and the sensitivity of sputum culture for TB lymphadenitis is 5.0–14.0%.⁴ TB of preauricular abscess is extremely rare: only one case report has been found in a review of literature, and it happened to be a form of preauricular lymphadenitis due to TB.⁵ Preauricular sinus is a benign malformation of the external ear. The incidence of preauricular sinus is 0.1–0.9% in the United States, 2.5% in Taiwan and 4.0% in Southwest Nigeria.^{6–8} The malformation of the auricle during the sixth week of embryogenesis and most of the preauricular sinus are unilateral and usually occur on the right side. Most of them are sporadic.⁸ Preauricular sinus is usually asymptomatic. Most patients present with a history of infection of preauricular sinus. The most common pathogens are *Staphylococcus epidermidis*, *Staphylococcus aureus*, *Streptococcus viridans*, *Peptococcus species*, and *Proteus species*.⁹ Once it presents as an infection, a systemic antibiotic should be given, and if an abscess is formed, incision and drainage should be performed with pus culture and gram stain.

Case report

A 31-year-old female with a previous history of preauricular abscess, off and on. The first episode of infection was 2 years ago. She came to the Otolaryngology Clinic at Panyanantaphikkhu Chonprathan Medical Center, Srinakharinwirot University (PCMC). She presented with preauricular swelling that had started³ weeks previous. She had no discharge from the ear pit. She had no cough, no weight loss, and no fever or any night sweat. She has no history of exposure to TB, and no known systemic disease. The patient had been given oral amoxy-clavulonic

acid for her preauricular sinus infection at a different outpatient clinic. Two weeks later it had become progressively more swollen. On examination, she had no fever, blood pressure was 150/104 mmHg, with a pulse rate of 93/min and a respiratory rate of 20/min. She weighed 81 kg. The ear nose and throat examination revealed normal findings. The preauricular abscess was 2.0x2.0 cm with tenderness. She underwent an incision and a pus culture for aerobic bacteria, and a gram stain for bacteria and acid fast bacilli. She had wet dressing with gauze drain twice a day with oral clindamycin 900 mg daily, but the surgical wound was still full of pus discharge (Figure 1). The AFB stain resulted in AFB 1+ from a private clinic and AFB was positive 3 AFB/100 F from Otolaryngology Clinic PCMC (Figure 2). The patient was started on anti-tuberculosis therapy consisting of INH 300 mg OD, Ethambutol 200 mg OD, Pyrazinamide 1,500 mg OD and Rifampin 600 mg OD. The HIV antibody was negative. The radiological view of the chest was normal. Resolution of the preauricular infection occurred after one week of follow-up. The anti-TB drugs were continued for the following two months with another four months of INH and Rifampin. The surgical excision of the preauricular tract was scheduled after 2 months of anti-TB drugs. Intraoperative finding: a sinus tract extended approximately 1.5 cm into the deep soft tissue, along the cartilage surface deep to the root of the helix. The sinus tract and surrounding soft tissue fibrosis were removed. The cyst was accidentally resected, and revealed a minimal amount of white creamy content. No lymph node was identified in the surgical field. The temporalis fascia appeared intact. Mycobacterium tuberculosis culture was negative after 8 weeks. Pathological report showed a cyst lined by stratified squamous epithelium with associated sebaceous glands with lamellate-keratin, which was surrounded with fibrotic connective tissue containing mild chronic inflammatory cell infiltration. No granuloma or malignancy was observed.

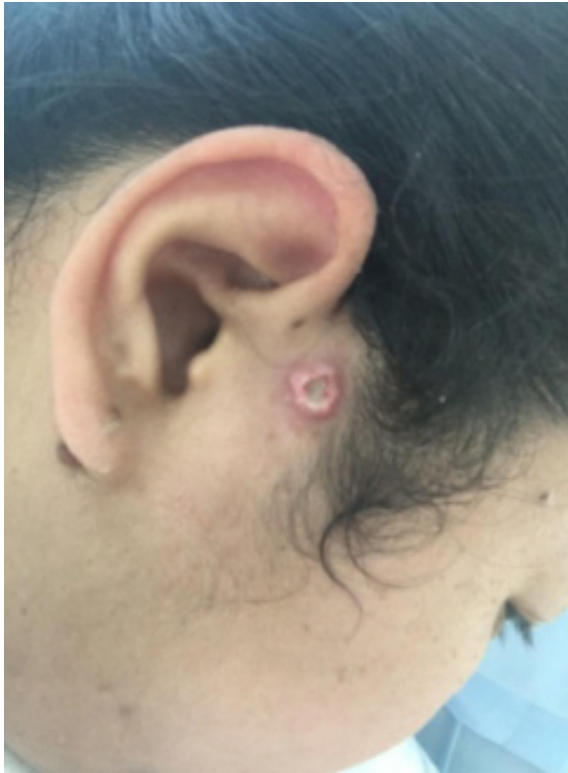

Figure 1 One week after incision and drainage with continuing clindamycin.

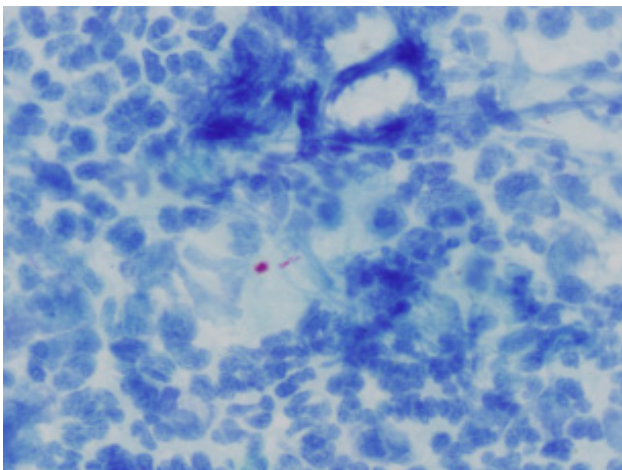


Figure 2 AFB stain from pus (Ziehl-Neelsen acid-fast stain, original magnification $\times 1,000$).

Discussion

Preauricular infection with TB is extremely rare even in endemic areas of TB. This is the first case report of TB of preauricular abscess. The most common presentation of head and neck tuberculosis is cervical lymph node TB, and the second most common localization of head and neck TB is the larynx. Cutaneous TB is the least common head and neck TB.¹⁰ The treatment of head and neck TB is the same regimen as pulmonary TB and other extrapulmonary TBs, except TB meningitis and TB of the bone and joint.¹¹ The etiology of TB of preauricular abscess is assumed to be the same as cutaneous TB, which is an invasion of the skin by *Mycobacterium tuberculosis*. We know as multibacillary forms which is a primary inoculation for TB (tuberculous chancre), typically following a penetrating injury, result is the direct introduction of *Mycobacterium* into the skin or mucosa of an individual with no previous TB infection.¹² This case emphasizes that TB should be considered in an unresponsive preauricular abscess after treatment as a usual bacterial infection, even though the patient has no history of immunocompromise host contact with TB.

The investigation is a demonstration of acid-fast bacilli (AFB) in pus stain, and the definitive diagnosis of TB is a culture of *Mycobacterium tuberculosis* organism from pus or any specimen obtained from the patient. The culture of TB takes 4–8 weeks and could cause a delay in treatment; thus, if AFB is found in the pus stain, treatment should be started immediately. This case, was bacteriologically confirmed, according case due to the WHO definition of a TB case (a biological specimen is positive by smear microscopy).¹³ Because there was only a small amount of AFB, only 3 cells presented in a high field at the time the culture was obtained, it became a culture negative case. Intraoperative finding and pathological finding indicate preauricular sinus infection. There was no granulomatous change, which may be due to the

short period of infection. Nonetheless, the patient clinically responded well to the anti-TB drug.

Treatment is not only starting anti-TB drugs, but also an excision of the preauricular sinus. Surgical excision can confirm a valid diagnosis of the specimen. Furthermore, it can remove the cause of the infection and help with assessment of treatment outcome. The protective mechanisms of TB involving granulomatous response, the bacilli can also survive, protected from killing by immune cells.¹⁴ The fact that there is no granulomatous tissue left behind can be a direct indication that the infection is improving.

Conclusion

TB of preauricular abscess is extremely rare. In cases of unresponsiveness to antibiotics and surgical drainage, AFB stain of pus should be considered for the diagnosis of TB preauricular abscess. Treatment of TB of preauricular abscess is a course of standard anti-TB drugs, plus surgical excision.

References

1. Wiwatworapan T, Anantasetagoon T. Extra-pulmonary tuberculosis at a regional hospital in Thailand. *Southeast Asian J Trop Med Public Health* 2008; 39: 521 – 5.
2. Jittimane S, Kateruttanakul P, Madigan EA, Jittimane S, Phatkrathok S, Poomichaiya P, et al. Medical characteristics and tuberculosis treatment outcomes in an urban tertiary hospital, Thailand. *Southeast Asian J Trop Med Public Health* 2006; 37: 338 – 44.
3. Kruijshaar ME, Abubakar I. Increase in extrapulmonary tuberculosis in England and Wales 1999–2006. *Thorax* 2009; 64: 1090 – 5.
4. Canadian Thoracic Society and The Public Health Agency of Canada and Licensors. *Canadian tuberculosis standards*. 7th ed. Ottawa: Public Health Agency of Canada; 2013.
5. Sageerabanoo MA, Baskaran HG. Pre-auricular abscess due to mycobacterium Tuberculosis. *Journal of Clinical and Diagnostic Research* 2011; 5: 1283 – 5.
6. Meggyessy V, Mehes K. Preauricular pits in hungary: epidemiology and clinical observation. *J Craniofac Genet Dev Biol* 1982; 2: 215 – 8.
7. Tsai FJ, Tsai CH. Birthmarks and congenital skin lesions in Chinese newborns. *J Formos Med Assoc* 1993; 92: 838 – 41.
8. Adegbiyi WA, Alabi BS, Olajuyin OA, Nwawolo CC. Presentation of preauricular sinus and preauricular sinus abscess in Southwest Nigeria. *Int J Biomed Sci* 2013; 9: 260 – 3.
9. Scheinfeld NS, Silverberg NB, Weinberg JM, Nozad V. The preauricular sinus: a review of its clinical presentation, treatment, and associations. *Pediatr Dermatol* 2004; 21: 191 – 6.
10. Bruzgielewicz A, Rzepakowska A. Tuberculosis of the head and neck—epidemiological and clinical presentation. *Arch Med Sci* 2014; 10: 1160 – 6.
11. Lee JY. Diagnosis and treatment of extrapulmonary tuberculosis. *Tuberc Respir Dis (Seoul)* 2015; 78: 47 – 55.
12. Frankel A, Penrose C, Emer J. Cutaneous tuberculosis: a practical case report and review for the dermatologist. *J Clin Aesthet Dermatol* 2009; 2: 19 – 27.
13. WHO Global tuberculosis report. Definitions of TB cases recommended for use starting in 2013. Geneva: WHO; 2013.
14. Guirado E, Schlesinger LS. Modeling the mycobacterium tuberculosis granuloma – the critical battlefield in host immunity and disease. *Front Immunol* 2013; 4: 98.